



Samvedana hospital

samvedana hospital, Ellisbridge, Below Karanavati Hospital Building, Opposite Town Hall, Ellisbridge, Ahmedabad, Gujrat, 380006

Patient Name: Maher S Soni

Age: 25 Year(s)

Gender: Female

Patient Id: 201806001

Contact No: 9978501432

Date: 01-06-2018

Chief Complaints

Patient presents for follow-up. As indicated in the HPI, denies fevers or chills; endorses decreased appetite and a 5lb weight loss over the past 3-4 months; endorses fatigue. as all about mentions

Assessment Notes

Patient presents for evaluation of left ankle pain. Slipped on ice yesterday. Felt a pop. Pain currently 6 of 10.

History of Present Illness

This 62 yo female with a PMH notable for TTP in 1996 who presents with intermittent dizziness, nausea, vomiting, and diarrhea of about 1 week duration. In a patient who notes two weeks of feeling that it was a struggle to remember something that had happened only a few moments before

Precipitating Event

Significant for stroke, heart disease, breast cancer, melanoma.

History

This patient is thrombocytopenic, with a platelet count of 66. This is caused by her TTP, so its treatment will be to treat the TTP.

Permanent History

Required with rain-related items, and not just from the sky

Mental Status Examinations

Mental status – She is alert and oriented x 3, except that she thinks the year is 2008.

Lab Report

01/06/2018 09:45 AM - HB:38.5, ESR:12.5,

01/06/2018 09:45 AM - HB:9.7, ESR:25.2,

Allergies

Food Allergy Recorded by Dr. Mrugesh Vaishnav

Vitals

T:55 P:66 RR:77 BP:88 SpO2:99

T:150 P:160 RR:180 BP:190 SpO2:200



Samvedana hospital

samvedana hospital, Ellisbridge, Below Karanavati Hospital Building, Opposite Town Hall, Ellisbridge,
Ahmedabad, Gujrat, 380006

Body Composition

T:170 **P:**55 **RR:**19.031141868512 **BP:**1326.5

Diagnosis

Skin Problem - Primary

R_x

1. Cream Nourella (50 mg) 5 day(s)

After food

Take 1 tablet per month after food

take it empty stomach

2. Capule Antioxidants (150 mg) 5 day(s)

0-1-0 (After Food)

Once in the afternoon, after lunch

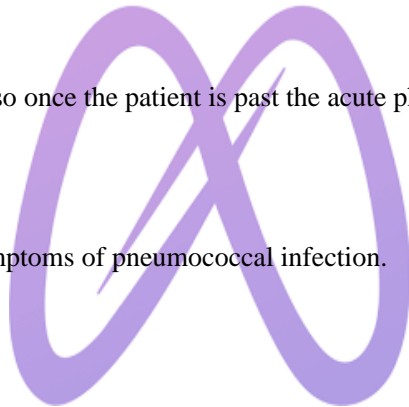
take it empty stomach

Investigation

Neoplastic processes can precipitate TTP, so once the patient is past the acute phase of her TTP, efforts will be made to improve her cancer screening.

Advice

This patient does not have any signs or symptoms of pneumococcal infection.



Doctor Name : Dr. Mrugesh Vaishnav